Good Case, Bad Case

Andy Little DO
andyglittle@gmail.com

Why a Case Report?

- Simple
- Easy
- A gateway to research
- Good for your CV

What makes a great Case

- Rare disease
- Rare presentation of common disease
- Rare treatment used
- Rare outcome

Things you'll want to collect

- Patient Consent
- Attending Approval
- Patient Medical Records
  - Presentation to discharge
  - Other Hospital Records
- Images if available

Then What?

- Write it up
- Editing
- Poster
- Submission for publication

Writing it up?

- Resources
  - BMJ Student Section http://student.bmj.com/student/view-article.html?id=sbmj.b5274
  - Henry Cohen Primer http://www.ashp.org/s_ashp/docs/files/AJHP_HenryCohen.pdf

Editing

- Your preceptor
  - Don’t be surprised if this does not help
- Your support group
  - Spouses, girlfriends, parents, etc.
- Your School
- Key is that it should be edited 3-5 times before you make a poster or submit it for publication

Making Your Poster

- Find a template
  - www.ohiocore.org
  - School
  - Hospital
- 3ftx5ft is the typical size
- Include pictures, labs, logos, etc.
- Don’t just copy and paste your paper into the poster
- Pick a Catchy Title

CENTERS FOR OSTEOPATHIC RESEARCH AND EDUCATION

Emergent Presentation of Ehrlichiosis

Dr. Jason Cheatham D.O. FACEP, Andrew Little OMS II

Southern Ohio Medical Center, Emergency Department,

Portsmouth, Ohio

Southern Ohio Medical Center

Very Good things are happening here

OHIO UNIVERSITY

College of Osteopathic Medicine

Abstract

Patients who suffer from an insect bite can be exposed to a host of diseases that will present with symptoms similar to certain life threatening or life altering diseases. This is a report of a 44-year-old Jane Doe who presented to a rural Emergency Department in Southern Ohio with nausea and vomiting for 4-5 days prior, while also complaining of fever for a 24 hour period. With a positive history of I.V. drug use over the previous 12 months it was initially suspected she was suffering from Hepatitis. Following a full workup for her complaint, which showed no specific cause of her symptoms, she was admitted, and later diagnosed with Ehrlichiosis, after which she was given a 10 day course of doxycycline, which resolved her medical condition. The epidemiology, presenting symptoms, pertinent lab values as well as other medical disorders that should be investigated while pursuing a diagnoses of Ehrlichiosis are discussed during the following case.

Introduction

Ehrlichiosis (caused by *Ehrlichia chaffeenis*) is a vector borne disease. The number of cases has been increasing since its original isolation in 1986 (1) and as many as 21 states reported cases of human erhlichiosis in 1990 (2). Commonly found in the southeastern United States, it has migrated into the Midwest, Northeast and South Central United States (1). According to the Centers for Disease Control the average annual Incidence of Erhlichiosis in the state of Ohio is between 0.01-1.99 cases per 1,000,000 persons (1). Carried by the Lone Star Tick (*Amblyomma americanum*) and the Dog tick (Dermacentor variabilis) (3), persons are typically inoculated by a direct bite, but transmission has also been documented by maternal-child transmission, blood transfusion or through direct contact with infected deer (4). It takes between 1 to 2 weeks for symptoms to appear after transmission(4).

Most patients present with some but not all of the following symptoms: fever, malaise, myalgia, headache, chills, nausea, vomiting, arthralgias and cough (1,5). Upon lab testing, patients have lab results As seen in **table 1**. It is important that when patients present with these symptoms That two things are done; make sure there is a documented tick bite and consider other diagnoses.

A patient presenting with the above symptoms and lab results, blood tests for antibodies against *E. chaffeenis* and *B. burgdorferi*. Although testing of an attached tick for Erlichiosis is more sensitive and specific for the diagnoses of Erlichiosis, this is rarely possible because the patient has already removed the tick (4). In these cases the aforementioned blood work is adequate for a diagnoses (4,5). Once a diagnosis is established, the patient should then be put on doxycycline for 10 days, and their aminotransferases should be monitored and a decrease should be seend as the infection is cleared by the patients immune system (4,5,6).

Case

A 44 year old female presented to the emergency department with complaints of nausea and vomiting with occasional diarrhea , intermittent abdominal pain, weakness, shakiness and, fever, with new onset back pain and chronic right shoulder pain were documented. Her vital signs were **BP** 89/43, **P** 94, **R** 16 **T** 101.6 F. The patient was on the following medications: OTC Pepcid, Zantac, Bismol; and Darvocet all of with no relief. Patient history included a history of Intravenous drug use within the previous year, and she denied tick bites during here stay in the emergency department.

Upon physical examination the patient was awake and appeared to be in mild distress. She had dry mucous membranes with tongue coating noted, and lymphadenopathy was appreciated on the posterior left neck. Tachycardia and, diminished breath sounds bilaterally were noted, and right upper quadrant pain was observed with deep palpation, but without Rebound. The Following labs were ordered. (See Table 2).

Table 1: Common Lab results for patient with Erlichiosis

1)Leukopenia
2)Anemia
3)Thrombocytopenia
4)Elvated Aminotranferases (AST/ALT)
5)Elevated Lactate Dehydrogenase
6)Elevated Alkaline Phosphatase

Table 2: Pertinent Lab results while in the Emergency Department

Bolded: High *Italicized/underlined: Low*

Test Name	Result
Portable Chest X-ray	Normal CXR
Glucose Scan	97
Urinalysis	Urine WBC: **16** Urine RBC: **2** Urine Protein: **1+** All other values Negative
Urine Tox	Urine Opiates: Positive All other values Negative
Complete Blood Count (CBC) with Differential	WBC: ***3.7*** HGB: 11.5 HCTL 34.0 PLT: *48* All other values were negative
BMP	BUN: **33** CREAT: **1.9** All other values were negative
Liver Profile	AST: **629** ALT: **449** ALP: **304** All other values were negative
Acute Hepatitis Panel	All were negative
Arterial Blood Gas	PCO2: *24* PO2: *76* HCO3: *16* All other values were negative
Blood Culture	No growth of aerobic or anaerobic bacteria
Spinal Fluid	WBC: **26** RBC:**26** Protein: **63** Culture: No Growth
Biliary Tree Ultrasound	1.3 cm gallstone visualized, no acute cholecystitis noted

Case (Cont.)

After initial blood work results were received, a hepatitis profile and a biliary tree Ultrasound were also ordered. The results of the hepatitis profile showed the patient was negative for hepatitis A, B and C. Biliary tree ultrasound showed a 1.3cm gallstone, without evidence of acute cholecystitis. Later during her stay, the patient's abdominal pain increased, she also complained of a severe headache and her temperature rose to 102.5˚ F. Broad spectrum antibiotics were given and a lumbar puncture was performed to rule out meningitis. After this workup the patient was admitted to the hospital Where she admitted to Being bit by a tick two weeks prior. Acute ehrlichia titers were run and were positive, after which she was started on a 10 day doxycycline regimen. After completionof her antibiotics she had a full recovery.

www.bugguide.net/node/view/16110

References

1. *Ehrlichiosis: Statistics*. (2008, April 1). Retrieved July 17, 2009, from Centers For Disease Control and Prevention: www.cdc.gov/ticks/disease/ehrlichiosis/statistics/.html
2. Johan S. Bakken MD, J. S.-M. (1994). Human Granulocytic Ehrlichiosis in the Upper Midwest United States. *Journal of the American Medical Association* , 212-218.
3. Bratton M.D., R. L., & Corey M.D., G. R. (2005). Tick-Bourne Disease. *American Family Physician* , 71:2323-30, 2331-2.
4. Daniel J Sexton, MD (2009, January 23). *Human Ehrlichiosis and Anaplasmosis*. Retrieved July 17, 2009, from UpToDate: www.utdol.com/online/content/topic.do?topicKey=tickflea/5429
5. Burke A Cunha, MD (2008, October 16). *Ehrlichiosis*. Retrieved July 17, 2009, from Emedicine: www.emedicine.medscape.com/article/235839
6. *Ehrlichiosis: Questions and Answers*. (2009, January 13). Retrieved July 17, 2009, from Centers for Disease Control and Prevention: www.cdc.gov/ticks/diseases/ehrlichiosis/faq.html

Acknowledgements

Would like to acknowledge Dr. Wayne B Wheeler MD for helping get patient consent after her admission to t hospital . Also would like to acknowledge and thank the nursing staff at the SOMC Emergency Department fo helping treat and manage this patient, during her stay in the emergency department.

Also to Grace Brannan PhD, Director of the CORE office for her help in writing and preparing this case submission to numerous journals.

Genital Warts Complicated by Flesh Eating Bacteria

CENTERS FOR OSTEOPATHIC RESEARCH AND EDUCATION

Andrew Little OMS IV, Jason Ashbaugh DO
Affinity Medical Center Emergency Department
Massillon, Ohio

Affinity MEDICAL CENTER
Close to you.

OHIO UNIVERSITY Heritage College of Osteopathic Medicine

Abstract

Necrotizing Fasciitis is a medical and surgical emergency that requires prompt intervention [1]. The hallmarks of this process include fever, pain out of proportion, crepitance upon palpation of the abscess, and areas of erythema. The case below describes a 43 year old African American male who presented to the emergency department with new onset groin pain, and was found to have Necrotizing Fasciitis underlying a chronic condyloma accuminatum complicated by squamous cell carcinoma.

Case Description

CC: Groin Pain

HPI: A 43 year old African American male was sent to the emergency room by his primary care physician with a chief complaint of groin pain emanating from a chronic groin mass and right upper thigh swelling. The patient has a chronic inguinal condyloma that has increased in size become painful, red, opened and has begun draining over the past few days. The patient rated his pain at 10 out 10 which becomes unbearable and out of proportion with touch and movement.

ROS:

- Positive for right groin pain, swelling of right inguinal area, malaise and anorexia for the past 3-4 days because of pain and a chronic condyloma.
- Negative for fever, chills, night sweats, blurred vision or dizziness. Denies Chest pain, shortness of breath, nausea vomiting or diarrhea, dysuria or urethral discharge. The patient also denies a known history of known sexually transmitted diseases.

PMHX: chronic condyloma that has increased in size over the past 20 years

FMHX: diabetes mellitus, hypertension

SHX: right knee arthroplasty

Social HX: 20 year pack smoking history, occasionally consumes alcohol, denied the use of recreational drugs. He is currently married. Admits to multiple sexual partners during adolescence.

Medications: patients take no current medications

Allergies: NKA

Case Description (Cont.)

Physical Exam

VITALS: T: 98.3° F (orally), blood pressure of 105/71, pulse of 107, respirations of 18 and pulse oximetry of 99% on room air.

HEENT: WNL

LUNGS: CTA Bilaterally

HEART: S1, S2 no murmurs gallops or rubs appreciated

ABDOMEN: Soft, non tender, positive bowel sounds in all four quadrants

PELVIC/GROIN: A large fungating condyloma located in the right groin area measuring 18 cm long, 4 cm tall, with its width ranging from 4cm wide in the right inguinal fold swelling to 14 cm wide in the patient's right upper thigh. Crepitous was noted on exam.

Additional: Condylomas were also appreciated on the patient's penis, rectal area and scrotum.

Lab Results

Complete Blood Count	
WBC	19.1 ↑
RBC	4.71
Hb	13.3 ↓
Hct	39.8 ↓
Plt	288
Bands	18 ↑

Basic Metabolic Panel	
Na+	133 ↓
K	3.6
Cl	97 ↓
CO2	19.5 ↓
BUN	11
Cr	1.3
Glu	331 ↑
Anion Gap	16.5 ↑

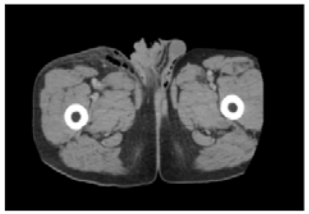

Figure 1. Coronal Image showing an irregular fungating right skin mass with underlying inflammation and subcutaneous emphysema

Figure 2. Sagital view showing condyloma with underlying subcutaneous emphysema and swelling. A large walled off density which was later found to be the central abscess

Conclusions

Patient Disposition:

- Transfer to a larger academic center
- Surgical debridement of his inguinal area, which included removal of his chronic condyloma; was found to have Squamous Cell Carcinoma
- Wound cultures which grew multiple bacteria (predominately Group G Streptococcus)
- Had a prolonged ICU stay secondary to sepsis
- Diagnosed with Diabetes
- Patient had no further complication

Key things to remember:

- Necrotizing fasciitis is a condition caused by anaerobic and gram negative bacteria (i.e. Group G Strep, Bacteroides, Proteus and Enterobacter as in this case) [2-5].
- Common in areas of trauma, hypoxia, recent surgery, and medical compromise [3,4].
- Hallmarks are fever, pain out of proportion, crepitance upon palpation of the abscess, and areas of erythema.
- The diagnoses is best made by incising the suspected abscess, looking for visual clues of necrosis [3].
- Early recognition and diagnoses is key in affecting overall mortality related to Necrotizing fasciitis.

References

1. Mills MK, Faraklas I, Davis C, et al. Outcomes of treatment of necrotizing soft tissue infections: results from the National Surgical Quality Improvement Program Database. *Am J Surg*. 2010;200: 790-797.
2. Weinburg AN. Group C and group G streptococcal infection. UpToDate. Available at http://www.uptodate.com/contents/group-c-and-group-g-streptococcal-infection Accessed May 11, 2011.
3. Maynor M. Necrotizing Fasciitis. eMedicine web site. Available at: http://emedicine.medscape.com/article/784690-overview. Accessed November 3, 2010.
4. Edlich RF, Cross CL, Dahlstrom JJ, et al. Modern Concepts of the Diagnoses and Treatment of Necrotizing Fasciitis. *J Emerg Med*. 2010; 39:261-265.
5. Abbott IJ, Spelman D. Bacteriology and Management of Necrotizing Soft Tissue Infections. *J Emerg Med*. 2009;37:420-421.

Acknowledgements

I would like to thank the Nurses at the Affinity Medical Center Emergency Department for their assistance in the care of this patient, the Affinity Medical Center medical records department for their help in procuring the patients records from Akron City hospital. Also to the CORE Research Office for help in preparing this poster.

Now What?

- Present Poster
  - FOEM Competition at Spring Conference 2013
  - Your States Osteopathic Conference

- Submit to a Journal
  - Western Journal of Emergency Medicine
  - Journal of Emergency Medicine
  - Medscape Case Reports

Summary

- Case Reports have Validity
- Can be a “Gateway” to Research
- Can be rewarding ($$$)
- Can be a way of setting yourself apart